

# Is cervical disc prosthesis always good solution ?

L. Balabaud, S. Hansen, C. Mazel

Institut Mutualiste Montsouris, Paris

12th International Argospine Symposium

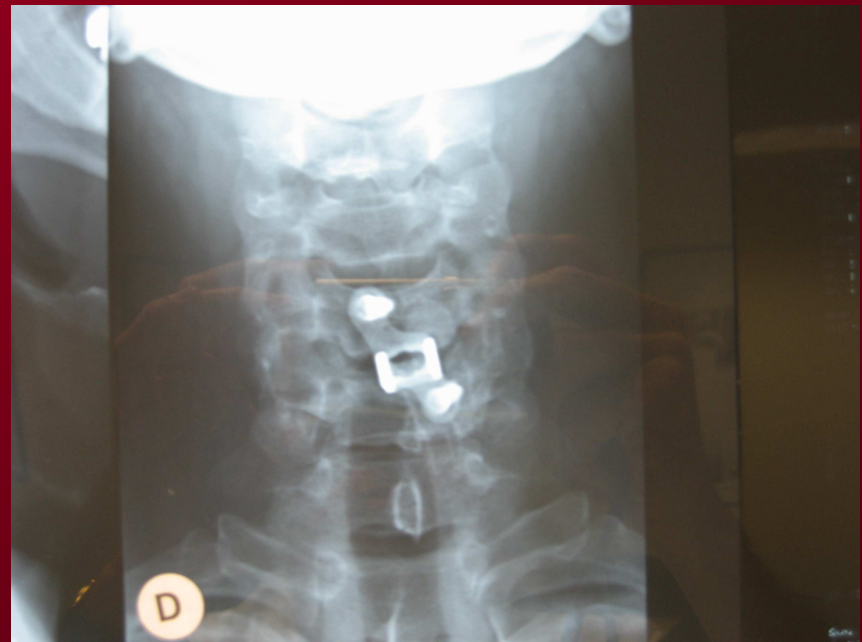
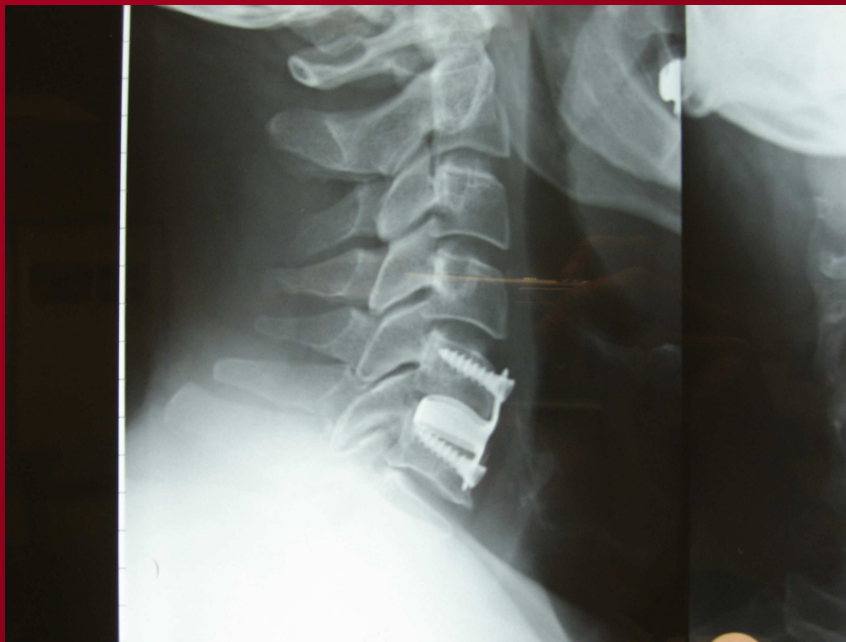January 24-25, 2008 Paris

# Patient History

- 37-year old male patient
- Neck pain and left radiculopathy in 2003
- MRI : left posterolateral herniation C5C6
- April 2003 : Anterior cervical approach and cage-plate C5-6

# Patient History

X-ray : Cage-plate C5-C6



# Patient History

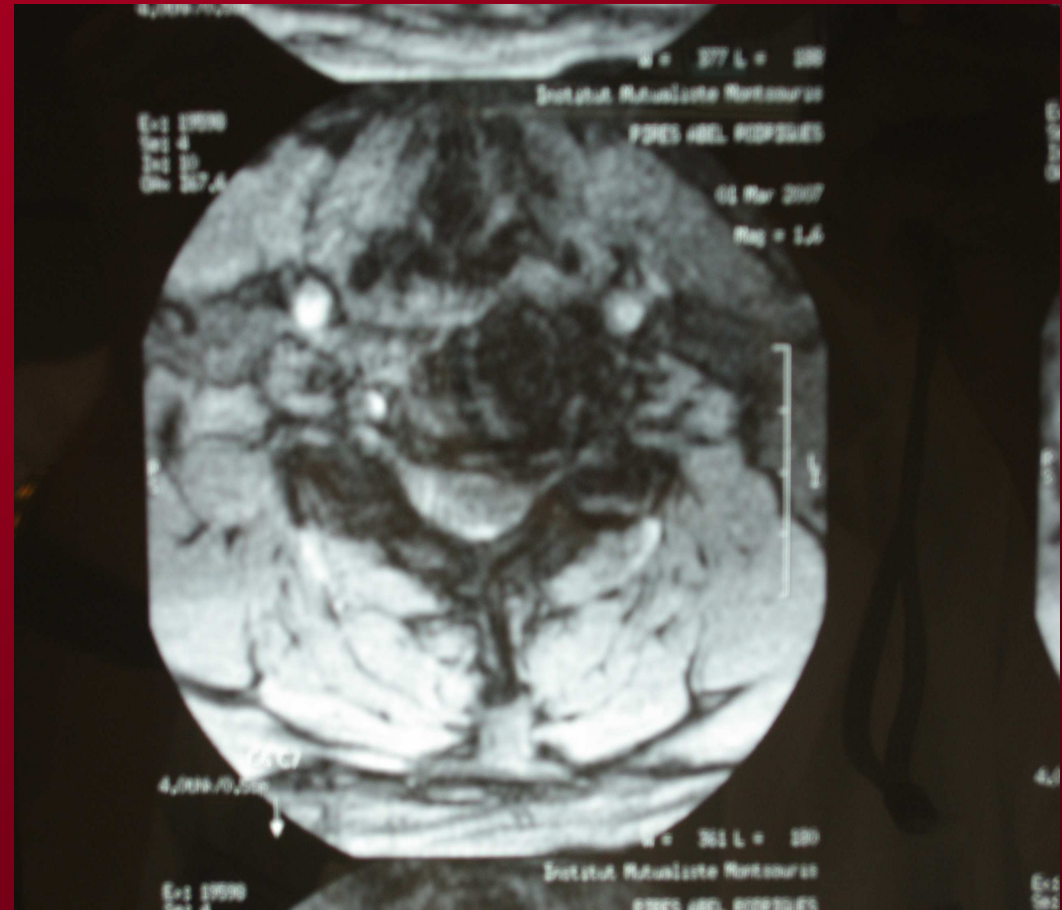- After 2 months, recurrence of the symptoms
- Medical treatment : NSAIDs, analgesics, oral cortisone, soft collar, physical therapy, spinal steroid injections.
- Electromyography in 2006 : left radiculopathy C7

# Patient History

- 2007 : Clinical examination :
  - Mechanical neck pain
  - Paresthesias and hypoesthesias in left hand
  - Left triceps and extensors of wrist and fingers 4/5
  - No signs of myelopathy
- MRI and CT-scan : left posterolateral herniation C6-7.

# Patient History

- MRI
  - Left posterolateral disc herniation C6-7





# Treatment Opportunities

- What would you choose?
  1. Medical treatment
  2. Surgical options

# Treatment Opportunities

- What would you choose?

1. Medical treatment



24%

2. Surgical options



76%



# Treatment Opportunities

- If you opt for surgical treatment, what would you choose?
  1. Cage-plate C6-7
  2. Double « discectomy » C5-6 and C6-7 and arthrodesis C5-7 after removal of cage-plate
  3. Corporectomy C6 and arthrodesis C5-7 after removal of cage-plate
  4. Cervical disc prothesis C6-7
  5. Laminectomy C5-7
  6. Other options?

# Treatment Opportunities

- If you opt for surgical treatment, what would you choose?

1. Cage-plate C6-7



2. Double « discectomy » C5-6 and C6-7 and arthrodesis C5-7 after removal of cage-plate



3. Corporectomy C6 and arthrodesis C5-7 after removal of cage-plate



4. Cervical disc prothesis C6-7



5. Laminecomy C5-7



6. Other options?

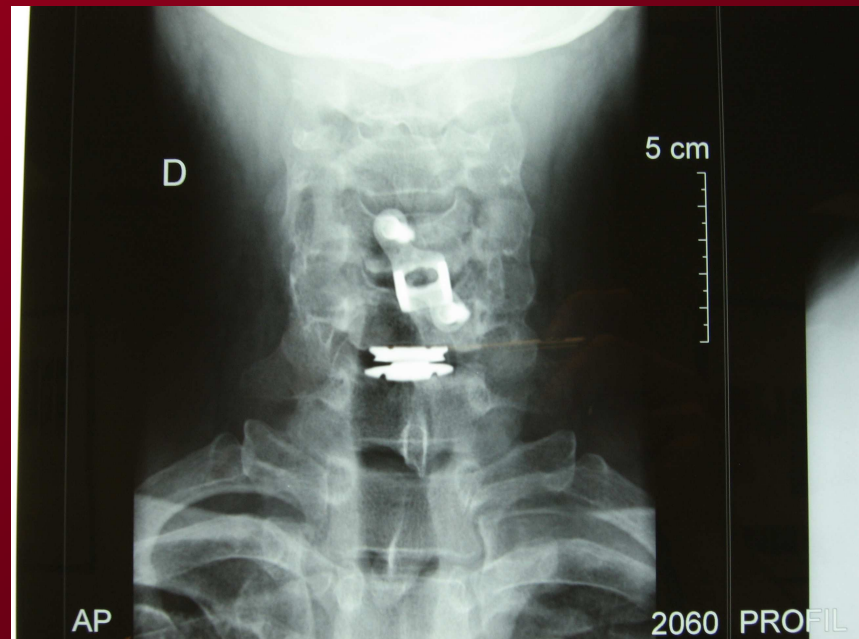
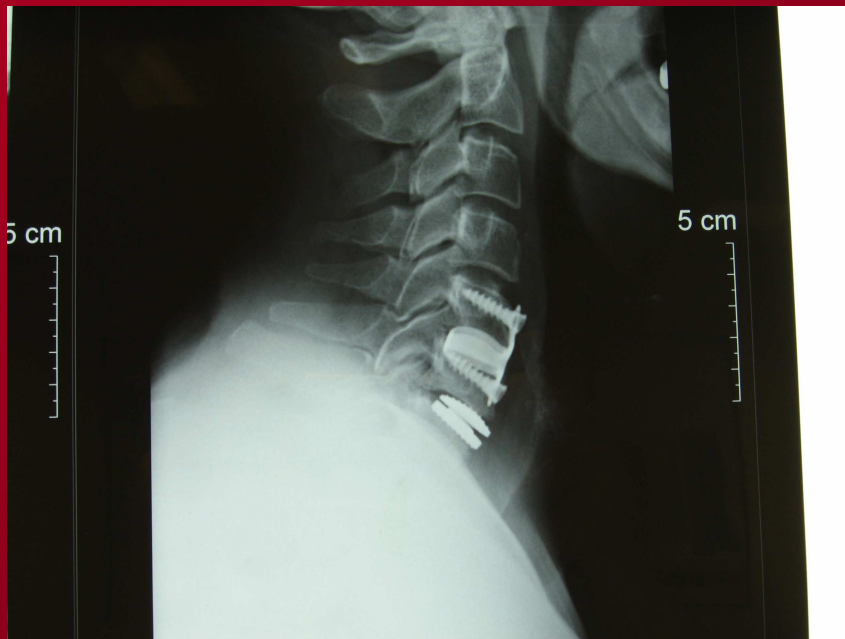
# Outcome

- In march 2007, the patient underwent a cervical disc prosthesis C6-7 after failure of medical treatment

# Outcome

Post-operative X-ray of cervical disc prosthesis C6-7

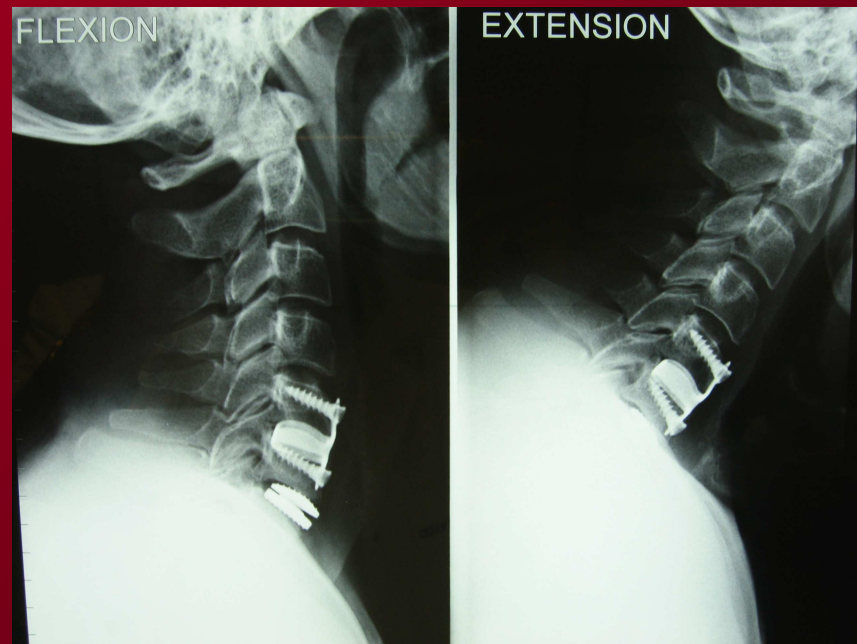


# Outcome

- After 3 months, neck pain and left radiculopathy recurrence without neurological defect
- X-ray : no modification of the cervical disc prosthesis
- Dynamic X-ray : No mobility
- MRI : no radicular or medullar compression

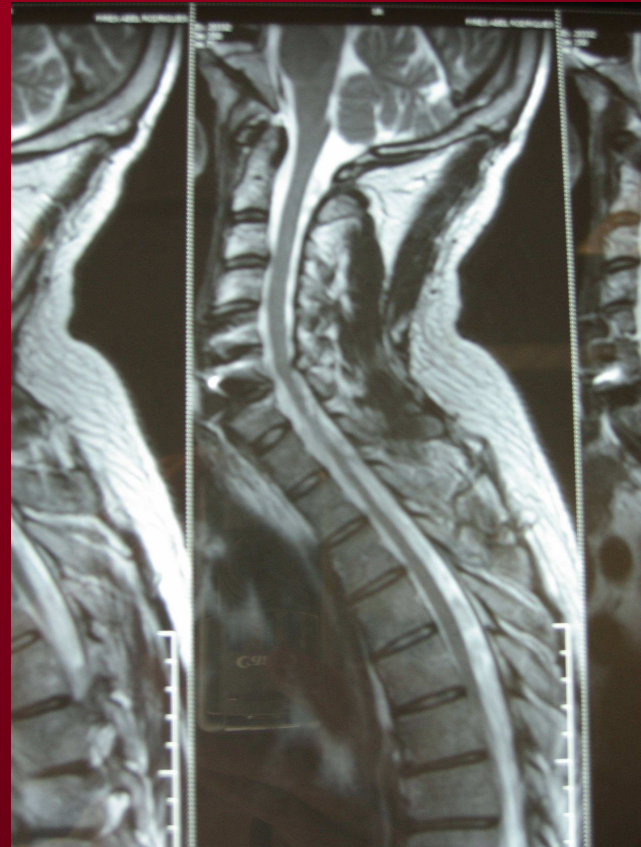# Outcome

- Dynamic X-ray:  
No mobility



# Outcome

- MRI :  
No radicular  
or medullar  
compression



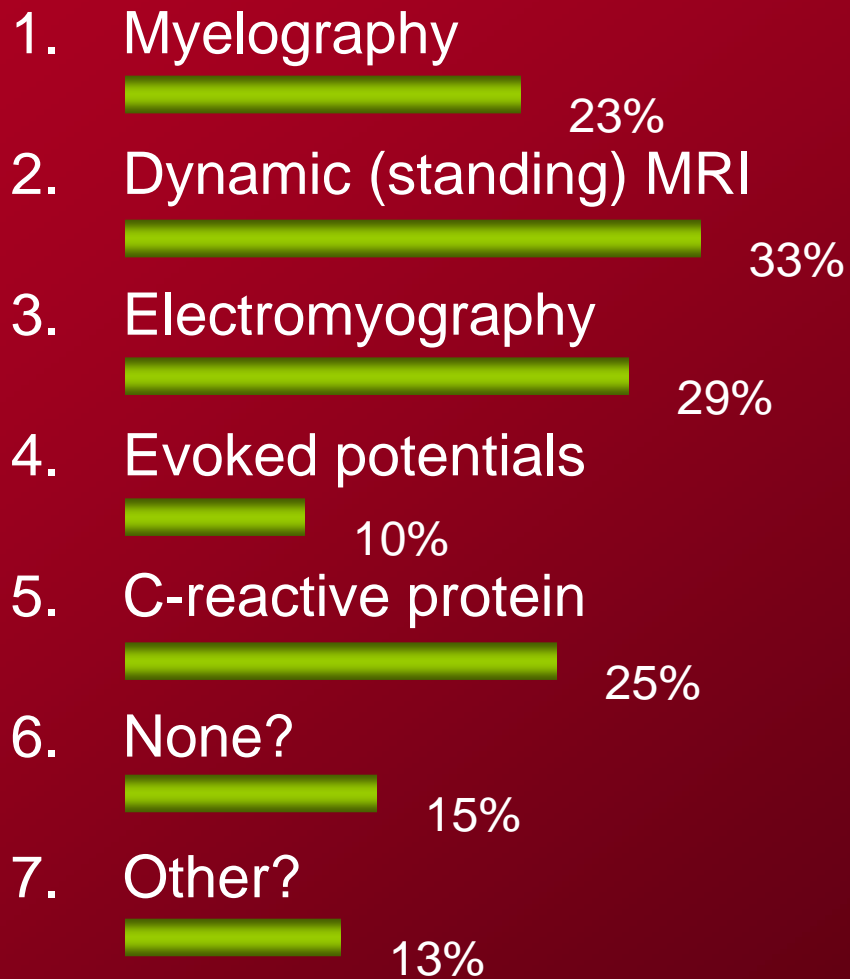


# Outcome

- Which complementary exams would you choose?
  1. Myelography
  2. Dynamic (standing) MRI
  3. Electromyography
  4. Evoked potentials
  5. C-reactive protein
  6. None?
  7. Other?

# Outcome

- Which complementary exams would you choose?





# Outcome

- What would you choose?
  1. Medical treatment
  2. Surgery

# Outcome

- What would you choose?

1. Medical treatment



2. Surgery










# Outcome

- If you decide for surgery, what do you choose?
  1. Cage-plate C6-7 after removal of cervical disc prosthesis
  2. Double « discectomy » C5-6 and C6-7 and arthrodesis C5-7 after removal of cage-plate and cervical disc prosthesis
  3. Corporectomy C6 and arthrodesis C5-7 after removal of cage-plate and cervical disc prosthesis
  4. Laminectomy C5-7
  5. Other options?

# Outcome

- If you decide for surgery, what do you choose?
  1. Cage-plate C6-7 after removal of cervical disc prosthesis  
 18%
  2. Double « discectomy » C5-6 and C6-7 and arthrodesis C5-7 after removal of cage-plate and cervical disc prosthesis  
 33%
  3. Corporectomy C6 and arthrodesis C5-7 after removal of cage-plate and cervical disc prosthesis  
 25%
  4. Laminectomy C5-7  
 8%
  5. Other options?  
 18%